



## The everStick™ Periodontal Splint by Dr Jansie van Rensburg

### What is meant by periodontal splinting?

The ligating, tying, or joining of periodontal involved teeth to one another in order to stabilize and immobilize the affected teeth. Mobile lower anterior teeth is a common complaint of dental patients with fairly advanced periodontal disease. The treating of these mobile teeth is often not very successful. The mobility is caused by a loss of supporting bone around the roots of the teeth. Even comprehensive periodontal treatment can not replace this missing bone and the prognosis for these teeth is poor. In the majority of cases the lower four incisors (the four teeth between the two lower canine teeth) are the teeth showing the first signs of mobility.

### Treatment options available for mobile teeth.

The most logical way to treat the mobility once the active periodontal disease is under control would be to splint these mobile teeth. Various methods of splinting are employed by dentists. The most frequently used technique is to use orthodontic stainless steel wire, bonded on to the lingual surface (or inside) of the teeth with composite (white filling material) which acts as a splint. This method has some success but the metal wire is quite rigid, and this type of splint tends to debond and fail in time.

Another disadvantage of this technique is that there is no true bonding between the metal wire and the composite filling material. There can also be aesthetic compromises with this technique, but the concept is good and these splints are an option if nothing better is available.

### What are other treatment options available to these patients in need of periodontal splinting?

The other options are mostly quite invasive and non-reversible. They can involve:

1. The extraction of the mobile teeth, and replacing the extracted teeth with a removable, partial denture.
2. Cast precious metal splints.
2. Extractions of the mobile teeth and replacement with dental implants. This may not be possible as these may require expensive and technique sensitive bone grafting procedures to provide a bony foundation for the implants as bone is lost in the periodontal disease.

### What does the literature says about splinting of teeth?

- Splinting was done since ancient times – *Weinberger 1948*

- *First described in 1902 – Matland & Matland*
- *Splinting lost its popularity in 1965 when Loe et al demonstrated bacterial association with gingivitis in man*
- *Fleszar showed that decreased mobility showed improved response to treatment - 1980*
- *Splinting improves gingival attachment – Burgett et al 1992*
- *Severely mobile teeth can be retained almost indefinitely (Pollack 1999)*
- *Nunn & Harrell concluded in a study over 24 years that "Occlusal treatment significantly reduced the progression of periodontal disease over time" – J Periodontol 2001.*

### But more importantly :

- **THE UNDERLYING PERIODONTAL DISEASE MUST FIRST BE TREATED**
- **SPLINTING IS NOT A QUICK SOLUTION TO SIMPLY STABILIZE LOOSE TEETH**
- **SPLINTING IS ALWAYS A PART OF A COMPREHENSIVE PERIODONTAL TREATMENT PLAN**
- **THE PATIENT MUST BE ABLE TO MAINTAIN THE SPLINT AND THE GINGIVAE AND KEEP THE AREA CLEAN, AND THUS DISEASE FREE.**
- **THE NECESSITY OF REGULAR FOLLOW-UP VISITS TO AN ORAL HYGIENIST CANNOT BE STRESSED ENOUGH**

### The everStick periodontal splint.

A relatively new technique for splinting mobile teeth is available in the everStick periodontal splint. The fibre reinforced composite periodontal splint stabilizes the mobile teeth and ensures a more comfortable chewing function for the patient. In this technique, glass fibre strands embedded into a polymer bis GMA matrix (resin) are used to reinforce the composite white filling material, which splints the mobile teeth together. The glass fibre bundles are embedded into the same matrix as is found in the composite (white filling) material and true bonding is obtained between the fibres and the composite filling material. The bond obtained between composite resins and etched enamel is the strongest bond possible in the oral cavity ( Bond strength of approximately 28 MPa). The flexural strength of the everStick fibres is as high as that of chrome cobalt cast metal but the splint has the advantage of not being completely rigid, but has a modulus of elasticity very close to that of dentine. The elasticity of the fibres may be beneficial to the healing of the

- *Repairing a fractured PFM bridge*
- *Bone regeneration*
- *Fibres and Implants*
- *Help! My direct bridge failed-trouble shooting tips*



### Inside this issue:

<i>Perio Splint</i>	1
<i>Direct facing replace-</i>	2
<i>Events calendar</i>	3
<i>A Course with a Difference</i>	3
<i>Clinical cases</i>	4
<i>Preventing failures</i>	6
<i>Contact Details</i>	6

# REPAIR OF A FRACTURED VENEER USING everSTICK™ NET

## CASE REPORT

**Professor Pekka K. Vallittu, DDS, PhD, CDT.**

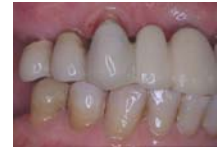Department of Prosthetic Dentistry and Biomaterials Research, Institute of Dentistry, University of Turku, Turku, Finland.

A 60-year-old woman with a loose veneer on the gold alloy FPD on her upper right canine was referred for repair. The FPD was made in 1997. Attachment of the original veneer to the gold alloy surface was achieved using retention pearls on the surface and by additional silanisation of the gold alloy surface. The repair was made via novel glass-fibre technology.



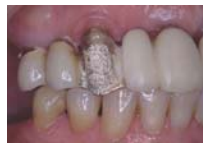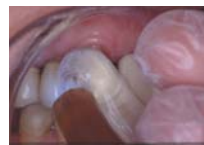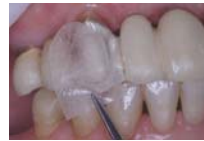A piece of everStickNet (Stick Tech Ltd) was placed on the repair surface and pressed against the opaquer layer with a transparent silicone instrument (Stick Refix D, Stick Tech Ltd), then initially light-cured for 40 seconds.

that no heavy occlusal contacts existed in the region of the repaired veneer.



### CONCLUDING REMARKS

FRC technology has proved its usefulness in many fields of dentistry, providing among other things, new solutions for repairs of existing gold alloy FPDs. The repair of veneers is one example of these applications.

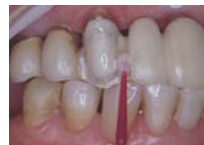
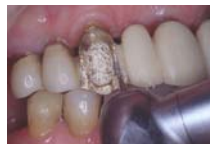
A groove was prepared on the crown with a diamond bur to provide macroscopic retention for the composite resin repair against the direction of the dislodgement force of the veneer.

After removal of the silicone instrument, the final light-curing of the everStickNet fibres was performed for 80 seconds. The thickness of one layer of everStickNet fibres is 0.06 mm. Excess glass fibres on the crown margins were removed with a scalpel. Light-curing resin (3M Adhesive Resin) was applied to the surface of the everStickNet and allowed to dissolve the outside layer of the everStickNet for 3 minutes

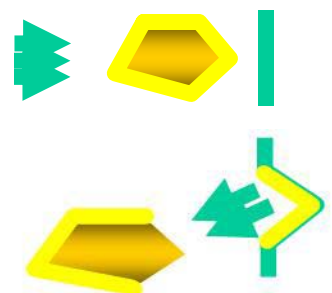
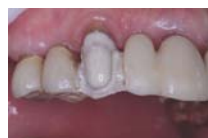### Bonding to metal made easy

Innovative chemistry applied by 3M-ESPE now enables the clinician to bond composite restorations directly to metal. Called 'Tribochemical Coating' the metal is sandblasted with a special sand, leaving a smear layer of silicon oxide on the surface to be bonded. The treated metal surface visibly changes colour to gun metal grey, enabling the clinician to ensure proper creation of tribo-plasma. After this layer is treated with silane, an opaque composite layer is applied and light-cured. It is strongly recommended that everStick™ Net reinforcement fibres are placed to optimize bonding prior to layering the restoration.



The surface was then roughened with a silicon-carbide stone for treatment using the repair materials in the repair kit (Clearfil Repair, Kuraray, Japan). The gold alloy surface was etched (K-etchant, Kuraray) and primed (Alloy Primer, Kuraray). This was followed by application of a layer of light-curing opaquer (Clearfil ST Opaquer, Kuraray) on the surface.

This enables the formation of the interpenetrating polymer network (IPN) bonding, of the resin to the FRC surface. After light-polymerisation of the resin for 20 seconds, a layer of hybrid composite resin (Z250, 3M-Espe, Seefeld, Germany) was applied and a new veneer was contoured. After light-curing the composite resin for 40 seconds and finishing the surface, articulation and occlusion were checked to ensure



*'Simplicity is the ultimate sophistication'* -  
**Leonardo da Vinci**



dental tissue. A fibre splint constructed in this way will form an reliable integrated structure which will give a potentially long term solution to the problem of mobile teeth. The fibres are transparent and unnoticeable when covered with the tooth coloured composite filling material. It is therefore possible to create an aesthetically pleasing splint on the inside of the mobile teeth.

**What does the procedure involve?**

Almost all cases of splinting are completed without local anaesthesia. A very shallow groove is prepared on the lingual (inside) surface of the teeth, which are to be splinted. The groove does not normally extend into the dentine of the teeth, but stays within the enamel where the best bonding will be obtained. Placing rubber dam isolation in these cases will simplify the procedure for both the dentist and the patient and is recommended.

**What happens if I have already lost a tooth?**

Another exciting benefit of the fibre bond periodontal splint is the possibility of replacing a missing tooth by building up an artificial tooth, directly onto the fibre splint. There are several methods of constructing a replacement tooth. In some carefully selected cases the patients own tooth can be bonded onto the fibre splint. In some cases the option of using an acrylic denture tooth can also be bonded to the splint. It is also possible to use Composite filling material to construct a replacement tooth. This composite tooth can also be reinforced with everStick fibres.

**What will a procedure like this cost me?**

The whole procedure is completed in one session and should not take longer than an hour. The fact that these fibres are high technology materials and the treatment requires special skills the fee charged might differ from practice to practice. The average fee for a splint from canine to canine will be £210 (to be discuss with the dentist).

**A DENTAL COURSE WITH A DIFFERENCE**

September 23, 2006

Combine the world-famous Hermanus Whale Festival with a hands-on training course on fibre reinforcement for dental composite restorations in South Africa.



Take advantage of the favourable exchange rate and bring your family to South Africa for that well-deserved break. Attend the Whale Festival and explore the Western Cape, also in close proximity is the Arabella Golf Estate and Western Cape Spa.

Contact [admin@stickbond.com](mailto:admin@stickbond.com) for more details and assistance on accommodation and excursions.

**Training Events Calendar August-December 2006**

**August**

8 **Lecture** Tunbridge, Rose&Crown Hotel

**September**

- 4 **Lecture** Rochester, Kent
- 11 **Lecture** Maidstone/Cosmetic D
- 16 **Training** Holiday Inn Maidstone
- 18 **Training** Maidstone/Stonecourt
- 22 **Training** Wye, Imperial college

**October**

- 2 **Lecture** Crawley
- 6 **Lecture** Hastings
- 14 **Training** Hastings
- 20 **Training** Tunbridge, Rose&Crown Hotel
- 23 **Lecture** Brighton
- 27 **Lecture** Warsaw, Poland

**November**

- 7 **Training** Wales; Merthur Tyfil
- 13 **Lecture** Worthing
- 17 **Training** Brighton
- 20 **Lecture** Bexhill on Sea
- 27 **Lecture** Best Beech Inn,Wadhurst

**December**

- 4 **Lecture** Orpington
- 9 **Training** Hastings
- 16 **Training** Orpington

**PLEASE DIARISE THE DATES NOW.** Reminders will be sent out approximately 3-4 weeks prior to the lecture/training hands-on course.

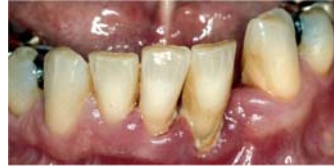## An Interesting Clinical Case

**Bone regeneration after stabilization of severely compromised lower anterior teeth. Clinical case by Dr Simome Veihelman.**

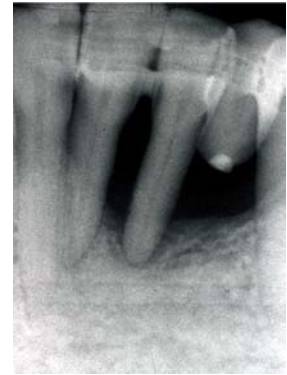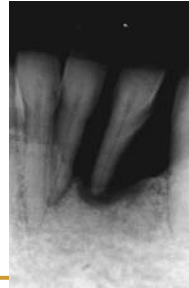Severely mobile teeth can be retained almost indefinitely (Pollack, 1999), provided that the teeth are stabilized, (splinted), the underlying periodontal disease is treated and that the patient can maintain proper oral hygiene around the splinted teeth.

The following photos demon-

strate the regeneration of bone around severely compromised teeth:

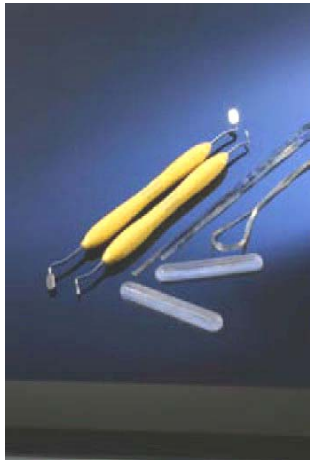

Pre-op photo's



20 months post-op

The complete clinical case was published in the German 'Paradontologie' Journal in 2004

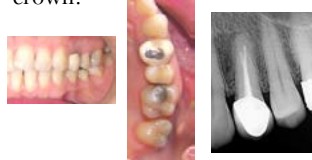

*'We could not let our receptionist work with a gap-toothed smile' - Dr Tommie Strydom*

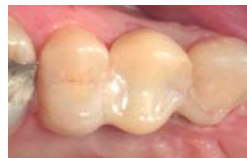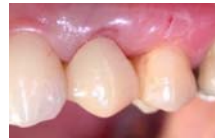## And one more.....

**A direct immediate bridge followed by an implant by Dr Tommie Strydom.**

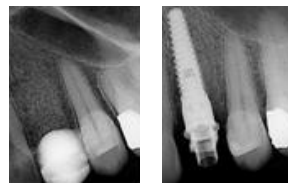'Approximately 3 months ago our receptionist complained about pain in the upper left area. X-rays revealed a large bony defect around a root canal treated tooth (24), restored with a porcelain fused to metal crown.



The prognosis was hopeless and it was decided to extract the tooth and place an immediate fibre reinforced composite bridge, followed by an implant at a later stage. After an atraumatic extraction and bone augmentation, the bridge I made myself was placed.

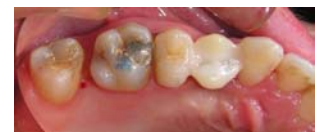
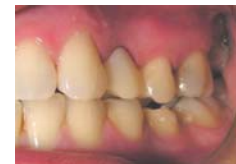
Six weeks later the bridge was removed and an implant (IBT 4x15, Southern Implants) was placed. I could only torque the implant about 20 nm and I decided rather to replace the bridge than immediate load the implant. I plan to give the implant about six months to integrate before I will attempt to place the final restoration.



As you would imagine, I could not let our receptionist walk around with a gap-toothed smile. It was thus nice to be able to place an immediate bridge without having to do major preparations on the adjacent teeth.

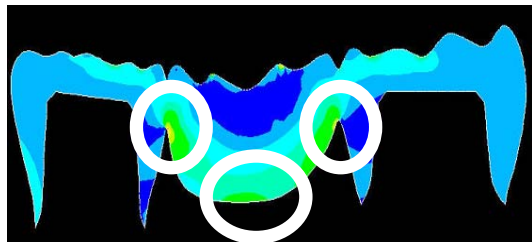
The everStick fibre bridge could be used again during the integration phase as I could easily adjust it to fit once I realized that immediate loading was not an option for this patient'.



Six weeks after the extraction. The bone healed nicely and I proceeded to place the implant.



## Help! My directly-placed bridge failed, -some trouble-shooting tips.



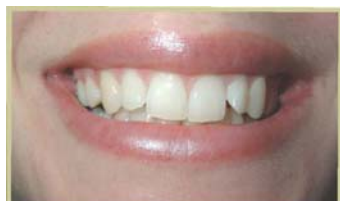Shinya Akikatzu & Matsuda T.

*‘Quality is not an act. It is a habit’ - Aristotle*

There are many pitfalls when using technique sensitive procedures restoring teeth to normal form and function. A systematic approach analyzing the reason why a restoration fails not only help the discerning clinician to prevent a similar occurrence, but will also enable the clinician to prescribe dental treatment with a predictable outcome.

De-bonding of surface retained structures is one of the main causes of failure of fibre reinforced structures. Several factors are important:

1. Proper moisture control-rubber dam isolation and an experienced operating team
2. Proper etching with 37% phosphoric acid (beware of self-etch systems on uncut enamel)
3. Rinse and dry properly-ensure that the enamel has a chalky white appearance prior to placing the bonding agent
4. Apply the bonding agent meticulously. Carefully follow the manufacturer’s instructions. Even though you might have been using bonding techniques for years, remember that bonding agents are very technique sensitive.
5. Is your curing light still functioning optimally? When was it last checked?
6. Never place the fibre directly onto bonded enamel. Always use flowable composite or normal composite as a luting cement



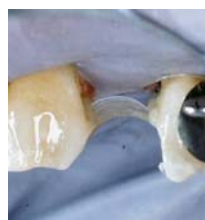**THE MORE YOU HAVE FIBERS, THE MORE YOU HAVE STRENGTH**

### Design of the construction.

Looking at the stress diagram, it is obvious that special attention be paid to the inter-proximal areas. Always ensure sufficient composite bulk in those areas.

Other important considerations are:

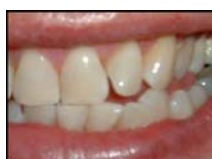1. Amount of reinforcement: one everStick™ C&B fibre per pontic in the anterior and premolar area, two everStick™ C&B fibres in the molar area
2. Remember to slope the fibre away from the occlusal surface in order to maximize the spreading of forces in the structure. (Tensile side of the construction)



3. Bulk of composite around the fibre: at least 1.5 mm composite is needed to withstand mastication forces
4. Reinforcing a pontic: composite on its own is not strong enough to withstand forces created by mastication over time. It is therefore essential to reinforce a pontic with transverse fibres, ideally placed underneath the cusps



5. Beware of lateral excursion forces



### Patient Selection

When considering fibre treatment, remember to discuss all possible treatment options, expected outcome and financial implications and **let the patient decide.** Take into account:

1. Oral hygiene
2. Immature enamel
3. Sclerotic enamel
4. Occlusal relation
5. Beware of a deep or closed bite
6. Beware of lateral excursions
7. Always apply sound fixed prosthodontic principles:
  - Span of the bridge
  - Check the supporting retainer units (check your X-rays)
  - Embrasure area (inter-dental papillae)
  - Maintenance (plaque control)

Ed.

Comments, suggestions, contributions: please contact the editor, Dr Klaas Visser.

### Our contact details:

6 Sandrock Park  
Hastings  
East Sussex  
TN37 7LP

Phone/Fax  
01424 755 238

Email: [fibrebond@tiscali.co.uk](mailto:fibrebond@tiscali.co.uk)

